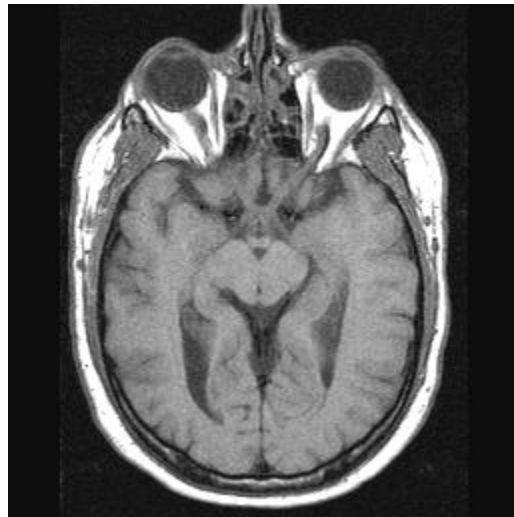
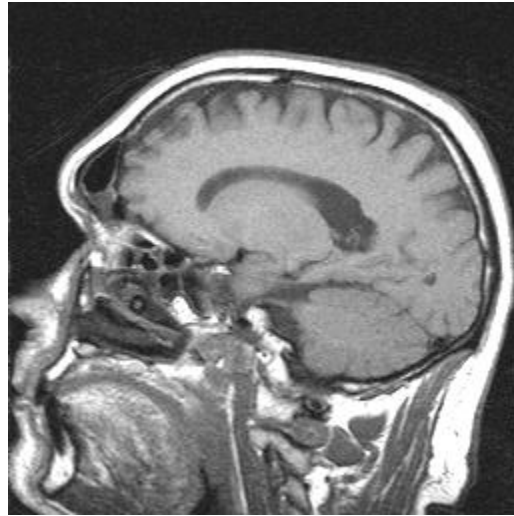
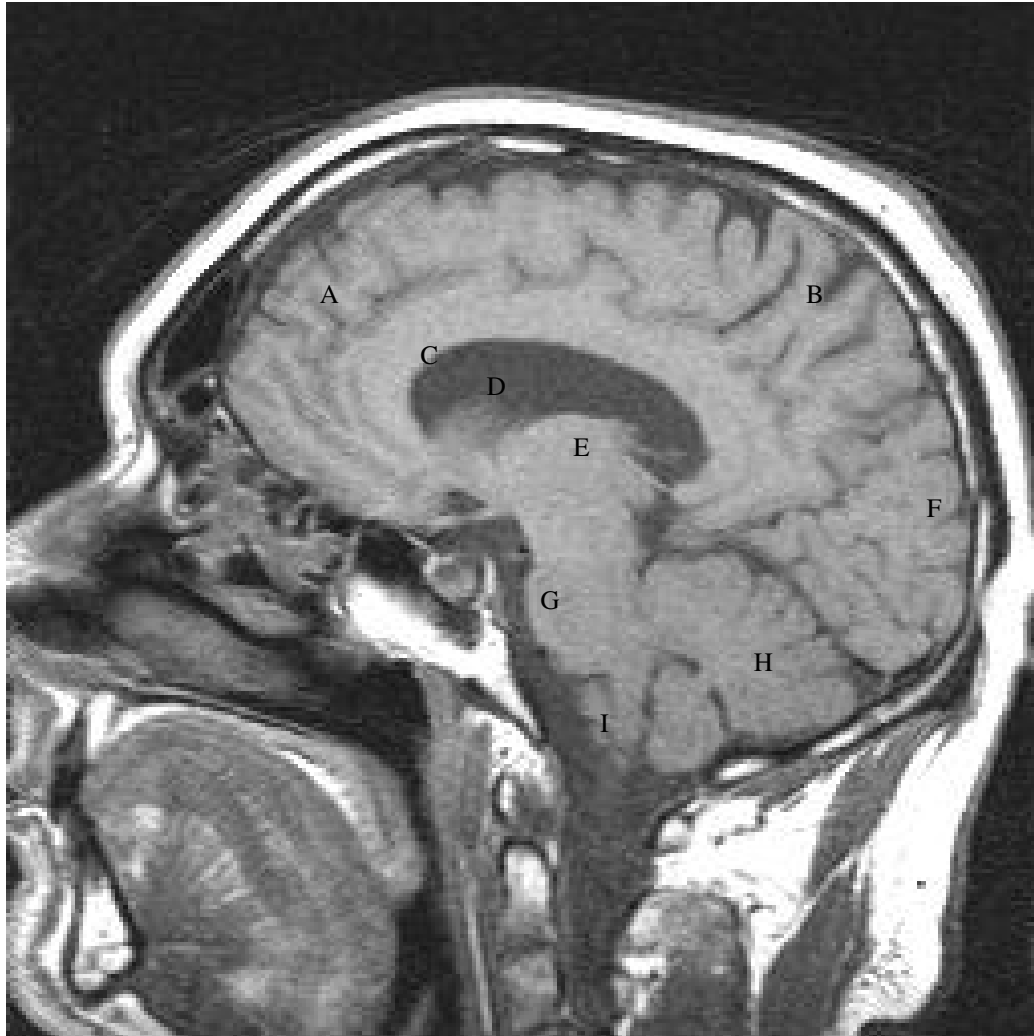


# Dr. Horowitz's Brain MRI 2006



More ↓



A frontal lobe

B parietal lobe

C corpus callosum

D lateral ventricle

E thalamus

F occipital lobe

G pons

H cerebellum

I medulla

[Return to Horowitz Mainpage click back button](#)